

Case Report

Corneal ulcer due to *Neocosmospora vasinfecta* in an immunocompetent patient

P. MANIKANDAN*, H. F. VISMER†, L. KREDICS‡, I. DÓCZI§, W. F. O. MARASAS†, M. BHASKAR#, R. ANITA*,
R. REVATHI* & V. NARENDRAN*

*Aravind Eye Hospital and Postgraduate Institute of Ophthalmology, Coimbatore, India, †PROMEC Unit, Medical Research Council, Tygerberg, Cape Town, South Africa, ‡Department of Microbiology, Faculty of Sciences, University of Szeged, Szeged, Hungary, §Department of Clinical Microbiology, Faculty of Medicine, University of Szeged, Szeged, Hungary, and #Department of Microbiology, Coimbatore Medical College, Coimbatore, Tamilnadu, India

We report a case of *Neocosmospora vasinfecta* keratitis in a 55-year-old man. While the patient did not recall any specific trauma or eye injury, he might have sustained a trivial wound during the course of his duties as a farmer. Direct examination of corneal scrapings revealed fungal filaments. As topical treatment with natamycin and econazole and subsequent systemic ketoconazole therapy failed, a full thickness therapeutic keratoplasty was performed. Post-operative treatment with amphotericin B and clotrimazole combined with cyclosporine resulted in a complete cure. The residual corneal infiltration in the recipient cornea became clear in a week. The fungal isolate was initially identified as a *Fusarium* species, but later reidentified through the use of morphological characteristics and sequence analysis of the internal transcribed spacer region as *N. vasinfecta*. The latter is a Hypocrealean fungus not hitherto reported as a causative agent of keratomycosis.

Keywords *Neocosmospora vasinfecta*, corneal ulcer, keratomycosis, India

Introduction

The genus *Neocosmospora* was established by Smith [1] for a species apparently pathogenic to various crops including cotton, watermelon and cowpea in the southeastern United States. *Neocosmospora vasinfecta*, a filamentous ascomycete belonging to the Hypocreales order of the Ascomycota division is a common plant pathogen predominantly found in tropical and subtropical areas [2] but has rarely been reported as being responsible for infections in humans. Known cases include a leg granuloma in a renal transplant recipient [3,4], posttraumatic osteoarthritis in an

immunocompetent patient [5], a fatal disseminated infection in a patient with acute nonlymphocytic leukemia [6] and an infection in a pediatric burn patient [7]. Occupational exposure to cotton may be a risk factor as *N. vasinfecta* has been isolated from intact senescent cotton roots [8]. Although *N. vasinfecta* has been reported to occur in plants in India [9,10], according to our knowledge, human infections due to this fungus has not been previously described in this country. Due to their rarity, 1-break/ >*N. vasinfecta* infections are often treated as if caused by *Fusarium* species, because the cultural morphology of *N. vasinfecta* anamorph resembles that of *Acremonium* spp. or *Fusarium* spp. [6]. However, since the antifungal susceptibility profile of *N. vasinfecta* may be different from those of *Fusarium* species, it is important to consider other etiologic agents when there is a poor clinical response to a possible *Fusarium* infection. Here we describe a case of fungal keratitis caused by *N. vasinfecta*.

Received 26 April 2007; Accepted 12 August 2007

Correspondence: Palanisamy Manikandan, Department of Microbiology, Aravind Eye Care System, Aravind Eye Hospital and Postgraduate Institute of Ophthalmology, Avinashi road, Coimbatore, Tamilnadu 641014, India. Tel: +91 422 4360400; fax: +91 422 2593030; E-mail: micro@cbe.aravind.org

Case report

A 55-year-old male presented at the cornea services of Aravind Eye Hospital, Coimbatore, South-India, on 1 June 2005 with pain, redness and defective vision in his left eye of 5 days duration. The patient could not remember any injury but as he was a farmer growing groundnuts and cotton he would have had frequent contact with cotton seed and soil. The patient had no significant medical history and his visual acuity in the right eye was 6/24 and in the left 4/60. Slit lamp examination of the right eye was significant only for lens changes (early cataract formation) while that of the left eye showed lid edema with 2+ (moderate) conjunctival and episcleral injection. There was a peripheral ulceration of about 5 × 3 mm in the inferotemporal quadrant of the cornea, with feathery edged infiltration of 6 × 3 mm extending up to the mid stroma surrounded by edema and endothelial deposits. An aqueous flare of 1+ (mild) and 2+ (moderate) cells were noted and the lens was found to be cataractous.

After instillation of 4% preservative free lignocaine (lidocaine), corneal scrapings were collected from the ulcer under aseptic conditions using a flame sterilized Kimura's spatula. Material obtained from scraping the leading edge and the base of the ulcer was inoculated directly onto 5% sheep's blood agar (SBA), chocolate agar (CA), and potato dextrose agar (PDA; 250 g of Potato slices, 15 g agar, 10 g dextrose and 1000 ml distilled water), and into brain heart infusion (BHI) broth. SBA, CA plates and BHI broth were purchased from Himedia Laboratories, Mumbai, India. Plates were incubated under aerobic conditions at 37°C, while the bottle containing PDA was incubated at 27°C.

Two direct smears were also prepared, one with 10% KOH and the other Gram stained. Microscopic examination of KOH wet mount revealed fungal filaments while only polymorphs were observed in the Gram stain slide. Based on the typical clinical picture and the KOH report, topical antifungal therapy was started with natamycin (5% suspension) and econazole drops (2%) every half an hour, along with homatropine (1%) administered three times a day. Samples inoculated on PDA and SBA resulted in fast growing, white colonies with cottony aerial mycelia. No bacterial growth was observed. Observation of the microscopic morphology after three days incubation revealed hyaline, straight or slightly curved microconidia suggestive of *Fusarium* species. *Fusarium* keratitis was diagnosed and the topical medications were continued as noted above. There was a 9 day gap in patient management as he failed to return for follow-up examination. Despite the administration of highly effective antimycotics, the

infection had progressed to full thickness corneal involvement with a 2 mm hypopyon. He was then admitted for inpatient therapy due to his poor compliance with the prescribed treatment.

Systemic ketoconazole (200 mg twice a day) was added to the topical antifungal therapy. The lesion had stabilized and the patient was discharged after 12 days. When reviewed 3 days later, the corneal infiltration remained the same but the endothelial deposits had coalesced forming a confluent plaque. A 4 mm thick immobile hypopyon was also noted. Acetazolamide (250 mg three times a day) was added to his treatment protocol. In spite of intensive therapy, the endothelial plaque was relentlessly progressive and extended up to the superior limbus by the 35th day. His vision had meanwhile deteriorated to 1/2/60. After 52 days of medical therapy, a large full thickness therapeutic keratoplasty was done. The involved corneal tissue with a clear margin of one mm was removed and plated onto SBA. The anterior chamber was irrigated with amphotericin B solution (50 µg/ml) and the cataractous lens was removed. A 9 mm donor corneal button was secured with 16 interrupted 10 O nylon sutures. The post-operative treatment consisted of amphotericin B (50 µg/ml) and 1% clotrimazole drops administered every half an hour and 2% cyclosporine twice a day. The recipient corneal button showed fungal growth after 3 days, which was again identified as *Fusarium* spp. Post-operatively, the graft was edematous with Descemet's membrane folds but was devoid of infiltration. In addition, the anterior chamber had formed well with 2+ (moderate) cellular reaction and a mid-dilated pupil. There were no fresh exudates in the anterior chamber. However, on the fourth postoperative day the recipient cornea showed stromal infiltration of about 2 mm at the 7.30 to 8.30 clock position adjacent to the graft host junction (Fig. 1). Scrapings were again obtained for culture, but no growth was found on any of the media. The residual corneal infiltration in the recipient cornea cleared in a week.

The fungal strain was sent to the PROMEC Unit of the Medical Research Council of South Africa and to the University of Szeged, Hungary to be identified and to determine its antifungal susceptibility.

Colonies of the fungus were fast growing on PDA at 25°C, flat, thin and appeared almost transparent at first with obvious rings forming as the colonies matured (Fig. 2a). Numerous ascomata (perithecia) formed within 10–14 days that gave the colony a punctate appearance (incubated at light and dark conditions at 25°C). Microscopic studies revealed hyaline, elongated to cylindrical conidia aggregated in slimy heads on conidiogenous cells developing on undifferentiated hyphae.

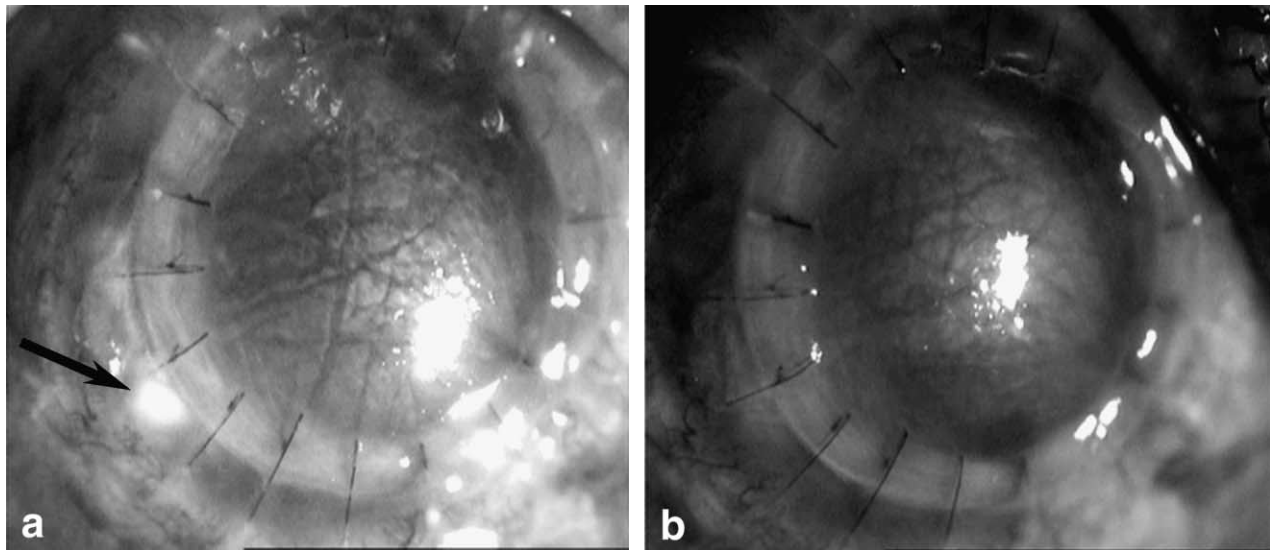


Fig. 1 (a) Slit lamp biomicroscopic view shows post therapeutic keratoplasty with infiltration of the recipient corneal edge indicated by an arrow (b) The infiltration cleared 1 week after therapy with amphotericin B.

Conidia sizes varied from 5–10 μm in length \times 2–3 μm wide, and were mostly single celled or with one septum. Some conidia appeared slightly curved. Intercalary chlamydospores were also observed. The microscopic morphology was consistent with *Acremonium* species. Perithecia were orange-brown in colour, subspherical (300–400 μm in diameter), multilayered and smoothed-walled, each with an apical pore (Fig. 2b and 2c). Cylindrical asci, 90–110 \times 10–12 μm in diameter, were present inside the ascomata, each containing 8 ascospores in a row (Fig. 2c). The ascospores were brownish, spherical to ellipsoidal, 10–15 \times 8–12 μm , with thick roughened walls and no germ pore present (Fig. 2d).

For the purposes of molecular identification, mycelia grown on yeast extract – glucose medium (0.5 g yeast extract, 10 g glucose, 20 g agar in 1000 ml distilled water) at 25°C for 10 days were subjected to DNA isolation by the GeneElute™ Plant Genomic DNA Miniprep Kit (Sigma-Aldrich, St. Louis, MO) in accord with the manufacturers instructions. Universal fungal primers were used to amplify the internal transcribed spacer (ITS) region of the rRNA gene complex, incorporating ITS 1, the 5.8S rRNA gene and ITS 2 [11]. Amplifications were performed in 50 μl volumes containing 5 μl 10X PCR buffer (ZenonBio, Szeged, Hungary), 200 μM each dNTP, 2.5 mM MgCl_2 , 0.5 μM each primer, 2.5 U of *Taq* DNA polymerase (ZenonBio, Szeged, Hungary), and 5 μl template DNA. PCR reactions were carried out in a T3 thermocycler (Biometra, Göttingen, Germany) with 1 cycle of 94°C for 5 min, 30 cycles of 94°C for 1 min, 48°C for 1 min, and 72°C for 1 min, and a final

elongation step at 72°C for 10 min. The product was purified using GenElute™ MINUS ETBr SPIN COLUMNS (Sigma-Aldrich, St. Louis, MO, USA) and then sequenced using the ITS 4 primer on an ABI 373A DNA sequencer (Applied Biosystems Inc., Foster City, CA, USA). The resulting 472 bp sequence was deposited in the GenBank database under the accession number EF373539. Sequence analysis was carried out by BLASTN similarity search [12] at the website of the National Center for Biotechnology Information (<http://www.ncbi.nlm.nih.gov/BLAST>). Two sequences of *N. vasinfecta* strains were identical with ours, while another three differed by a single base. The nearest *Fusarium* sequence was that of a *F. solani* strain with 98.73% similarity (Table 1).

On the basis of the macroscopic features, micro-morphology and the results of ITS sequence analysis, the strain was identified as *Neocosmospora vasinfecta*. Living cultures were deposited at the Department of Microbiology, Aravind Eye Hospital and Postgraduate Institute of Ophthalmology, Coimbatore, India (AEH 1402/05), at the collection of the Medical Research Council, South Africa (MRC 8633) and at the Centraalbureau voor Schimmelcultures (CBS 121152).

The E-test method (AB BIODISK, Solna, Sweden) for moulds was used to determine the minimal inhibitory concentration (MIC) values of the isolate to amphotericin B, fluconazole and voriconazole. In accord with the manufacturer's instructions, RPMI 1640 agar (15 g in 1000 ml) supplemented with 20 g glucose per 1000 ml medium [13] was used in the tests. The MIC of natamycin (5% suspension, Sun Pharmaceutical Ind.

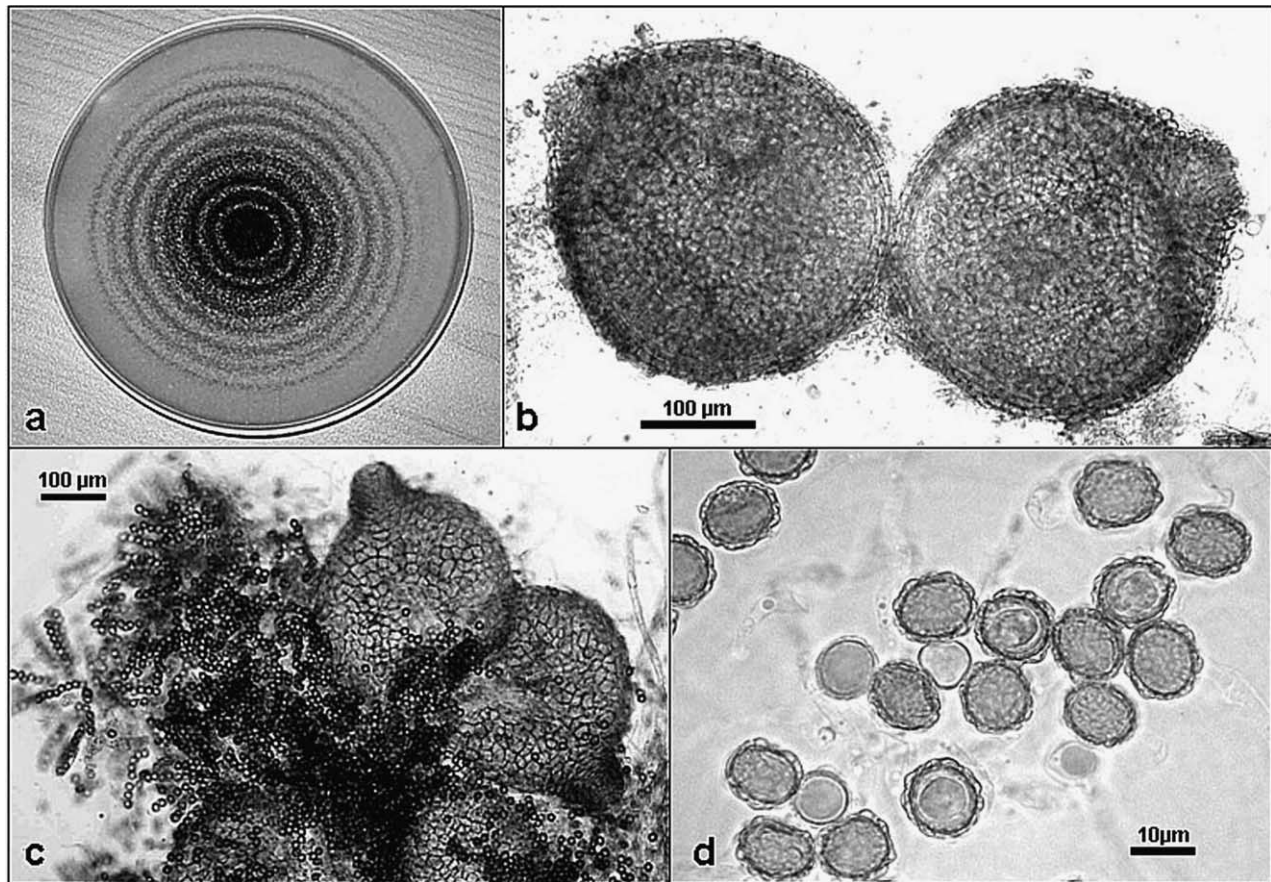


Fig. 2 (a) Culture of *Neocosmospora vasinfecta* grown on potato agar at 25°C for 14 days. The colony appears flat, thin and almost transparent. Rings with punctuate appearance, due to the presence of numerous perithecia, are apparent. (b) Microscopically the perithecia are orange-brown in colour, subspherical (300–450 µm in diameter), smooth-walled and each has an apical pore. Bar = 100 µm. (c) Perithecia with cylindrical asci 80–100 × 11–15 µm in diameter. Each ascus contains 8 ascospores. Bar = 10 µm. (d) Ascospores are brownish, spherical to ellipsoidal, 10.0–15.5 × 7.5–12.0 µm, have roughened cell walls and no germ pore. Bar = 10 µm.

Ltd., Halol, India), econazole (2% suspension, Aurolab, Madurai, India) and clotrimazole (1% suspension, Aurolab, Madurai, India) were determined by the broth microdilution technique NCCLS M38-A [14]. Both the Etests and microdilution plates were incubated at 30°C for 72 h. *Candida parapsilosis* ATCC 22019 was used as the quality control for econazole, clotrimazole, keto-

nazole and amphotericin B during the susceptibility tests. Results obtained for these strains were in accordance with the QC-ranges published for these isolates [15,16]. MIC values for natamycin, amphotericin B, ketoconazole, econazole and clotrimazole and proved to be >1024, 0.5, >32, >32, and >32 µg/ml, respectively. The strain proved to be resistant to natamycin,

Table 1 GenBank sequences most similar to EF373539

GenBank accession number	Strain designation	Number of overlapping bases	Sequence similarity (%)	Reference
L36627	<i>N. vasinfecta</i> NRRL 22166	472	100	[24]
AY381142	<i>N. vasinfecta</i> NRRL22497	472	100	[7]
AY381143	<i>N. vasinfecta</i> NRRL22500	471	99.79	[7]
AY381140	<i>N. vasinfecta</i> NRRL22499	471	99.79	[7]
AY381139	<i>N. vasinfecta</i> NRRL34174	471	99.79	[7]
AY381138	<i>N. vasinfecta</i> NRRL22436	470	99.58	[7]
AY381141	<i>N. vasinfecta</i> NRRL22423	469	99.36	[7]
DQ094720	<i>F. solani</i> FRC#s850	467	98.73	[25]

240 ketoconazole, econazole and clotrimazole at the highest concentration evaluated, while it was susceptible to amphotericin B which is in congruence with the success of the post-operative amphotericin B treatment.

Discussion

245 Current reports suggest a 44 to 56% increase in the prevalence of fungal keratitis in developing countries [17–19]. The use of contact lenses and the growing number of ocular surgeries may have contributed to this increased number of cases. *Fusarium* spp. and *Aspergillus* spp. are the fungi most commonly isolated in cases of keratitis [20,21]. However, a large number of other fungi have been implicated as the cause of such infections [22]. Accurate species identification and routine antifungal susceptibility testing are not feasible in most clinical practices.

250 The anamorph of *N. vasinfecta* and members of the genus *Fusarium* are morphologically similar [6]. In our case, the isolate was initially identified as *Fusarium* based on colony and micromorphology, but later reidentified and confirmed as *N. vasinfecta* once its teleomorph became apparent. Since the clinical presentation is similar in any given case of filamentous fungal keratitis, treatment was initiated with what is considered as the drug of choice, natamycin [21]. This therapy was supplemented with oral ketoconazole when the infection progressed to full thickness involvement of the cornea. Given the rarity of *N. vasinfecta* as a pathological agent, it was not considered in our differential diagnosis in this case. Therefore the therapeutic protocol was predicated on those antifungal agents known to be effective in infections caused by *Fusarium* spp. As noted, medical therapy failed and a therapeutic keratoplasty had to be performed. However, unlike other unresponsive severe fungal keratitis, there was significantly less anterior chamber inflammation. The iris was not boggy intra-operatively, neither was it necrotic with florid vascularization. The mild post-operative anterior chamber reaction was unexpected. This could have been the results of the unusually favorable response to amphotericin B. The presence of stromal infiltration at the recipient corneal margin could have been due to incomplete removal of all involved tissue or to lateral spread along the corneal lamellae. Since the initial topical antifungal therapy was ineffective, treatment with amphotericin B and clotrimazole was initiated post-operatively. As a result, the infiltrate in the recipient cornea resolved in one week. *N. vasinfecta* may be only capable of initiating a mild infection as evidenced by its very slow progression

290 or can only elicit a limited inflammatory response in an immunocompetent patient.

295 In spite of the fact that natamycin is acknowledged to be the drug of choice for *Fusarium* keratitis, medical failures have been associated with its use in up to 25% filamentous fungal keratitis cases [21,23]. In Aravind Eye Hospital, *Fusarium* keratitis constitutes about 56% of all cases of fungal keratitis and 34% of these infections fail to respond to this drug (unpublished data). Some of these cases might have been caused by less frequently encountered etiologic agents such as *N. vasinfecta* which mimic *Fusarium* but are unresponsive to natamycin. 300 However, since there are no data available on the *in vitro* natamycin susceptibility of clinical *N. vasinfecta* isolates, no general conclusions can be made as to the efficacy of natamycin in the treatment of *N. vasinfecta* keratitis. Although the patient in the present case did not report any trauma predisposing to the development of his keratitis, he reportedly used cotton seed as cattle feed. Furthermore, he resided in the Namakkal District, a place in Tamilnadu state well known for poultry and agricultural activities. Hence, we suppose that a trivial injury sustained during the course of his farming activities could have caused the corneal ulcer. 305 310

315 In a previous report describing a case of leg granuloma caused by *N. vasinfecta* the latency period between infection and clinical manifestation was suggested to be several years with a low level of inflammation [3,4]. Similarly, neither the incubation period nor the mechanism of infection could be determined in the case of a disseminated *N. vasinfecta* infection in a patient with acute nonlymphocytic leukemia [6]. The slow course of the infection and the immunocompetent state of the patient may also be of limited use in the diagnosis of ocular infections caused by *N. vasinfecta*. If the identification of the etiologic agents to species and/or antifungal susceptibility testing is not available, an early change in the therapeutic protocol in unresponsive cases may be effective in bring about positive clinical response. Early surgical intervention may also be useful in such unresponsive cases. 320 325 330

335 To our knowledge, the present case of fungal keratitis constitutes the first ocular infection caused by *N. vasinfecta* and only the fifth human cases worldwide caused by this unusual human opportunistic pathogen. Furthermore, the present study demonstrates that prompt and accurate identification of the aetiological agent is of great importance in order to administer the appropriate treatment in cases of corneal ulcers caused by fungi.

Acknowledgements

LK is a grantee of the János Bolyai Research Scholarship (Hungarian Academy of Sciences).

References

- 1 Smith EF. Wilt disease of cotton, watermelon and cowpea. *USDA Bull* 1899; **17**: 1–53.
- 2 Cannon PF, Hawksworth DL. A revision of the genus *Neocosmospora* (Hypocreales). *Trans Br Mycol Soc* 1984; **82**: 673–688.
- 3 Ben Hamida F, Achard JM, Westeel PF, et al. Leg granuloma due to *Neocosmospora vasinflecta* in a renal graft recipient. *Transplant Proc* 1993; **25**: 2292.
- 4 Chandener J, Hayette MP, de Bièvre C, et al. Leg tumefaction with *Neocosmospora vasinflecta* in a renal transplant patient. First human case report. *J Mycol Med* 1993; **3**: 165–168.
- 5 Kac G, Piriou P, Gueho E, et al. Osteoarthritis caused by *Neocosmospora vasinflecta*. *Med Mycol* 1999; **37**: 213–217.
- 6 Cornely OA, Chemnitz J, Brochhagen HG, et al. Disseminated *Neocosmospora vasinflecta* infection in a patient with acute nonlymphocytic leukemia. *Emerg Infect Dis* 2001; **7**: 149–152.
- 7 O'Donnell K. *Neocosmospora vasinflecta* infection in a pediatric burn patient: the registry of the first case in the American continent, a case report. 2003; Direct NCBI submission, accession numbers AY381138–AY381143. Available from: <http://www.ncbi.nlm.nih.gov>
- 8 Baird R, Carling D. Survival of parasitic and saprophytic fungi on intact senescent cotton roots. *J Cotton Sci* 1998; **2**: 27–34.
- 9 Farr DF, Rossmann AY, Palm ME, et al. Fungal databases, Systemic Botany and Mycology Laboratory, ARS, USDA. Accessed 24 March 2006 from: <http://nt.ars-grin.gov/fungaldata/bases/>
- 10 Vishwa D, Chaudhary RG, Mishra S, Khan AA. Occurrence of pigeon pea wilt caused by *Neocosmospora vasinflecta*. *Indian J Pulses Res* 2005; **9**: 254–255.
- 11 White TJ, Bruns T, Lee S, Taylor J. Amplification and direct sequencing of fungal ribosomal RNA genes for phylogenetics. In: Innes MH, Gelfand DH, Sninsky JJ, White TJ (eds). PCR protocols. Academic Press, San Diego, CA. 1990, 315–322.
- 12 Altschul SF, Gish W, Miller W, Myers EW, Lipman. DJ. Basic Local Alignment Search Tool. *J Mol Biol* 1990; **215**: 403–410.
- 13 Etest technical guide 10: Antifungal susceptibility testing of moulds. AB Biodisk, Solna, Sweden, 1999.
- 14 National Committee for Clinical Laboratory Standards. Reference method for broth dilution antifungal susceptibility testing of filamentous fungi; approved standard. NCCLS document M38-A. NCCLS, Pennsylvania, USA, 2002.
- 15 Guinet R, Nerson D, de Closets F, et al. Collaborative evaluation in seven laboratories of a standardized micromethod for yeast susceptibility testing. *J Clin Microbiol* 1988; **26**: 2307–2312.
- 16 Pfaller MA, Bale M, Buschelman B, et al. Selection of candidate quality control isolates and tentative quality control ranges for *in vitro* susceptibility testing of yeast isolates by National Committee for Clinical Laboratory Standards proposed standard methods. *J Clin Microbiol* 1994; **32**: 1650–1653.
- 17 Srinivasan M, Gonzales CA, George C, et al. Epidemiology and aetiological diagnosis of corneal ulceration in Madurai, south India. *Br J Ophthalmol* 1997; **81**: 965–971.
- 18 Prajna NV, John RK, Nirmalan PK, Lalitha P, Srinivasan M. A randomized clinical trial comparing 2% econazole and 5% natamycin for the treatment of fungal keratitis. *Br J Ophthalmol* 2003; **87**: 1235–1237.
- 19 Gopinathan U, Garg P, Fernandes M, et al. The epidemiological features and laboratory results of fungal keratitis: a 10-year review at a referral eye care center in South India. *Cornea* 2002; **21**: 555–559.
- 20 Dóczi I, Gyetvai T, Kredics L, Nagy E. Involvement of *Fusarium* spp. in fungal keratitis. *Clin Microbiol Infect* 2004; **10**: 773–776.
- 21 Thomas PA. Current perspectives on ophthalmic mycoses. *Clin Microbiol Rev* 2003; **16**: 730–797.
- 22 De Hoog GS, Guarro J, Gené J, Figueras MJ. Atlas of Clinical Fungi. 2nd edn. Centraalbureau voor Schimmelcultures, Utrecht, The Netherlands, 2000, 289–290.
- 23 Poole TR, Hunter DL, Maliwa EM, Ramsay AR. Aetiology of microbial keratitis in northern Tanzania. *Br J Ophthalmol* 2002; **86**: 941–942.
- 24 O'Donnell K, Gray LE. Phylogenetic relationships of the soybean sudden death syndrome pathogen *Fusarium solani* f. sp. *phaseoli* inferred from rDNA sequence data and PCR primers for its identification. *Mol Plant Microbe Interact* 1995; **8**: 709–716.
- 25 Zhang N, O'Donnell K, Sutton DA, et al. Members of the *Fusarium solani* species complex that cause infections in both humans and plants are common in the environment. *J Clin Microbiol* 2006; **44**: 2186–2190.