

# Optical iridectomy in children with corneal opacities

Kannan Sundares, MS,<sup>a</sup> Jitendra Jethani, MS, DO, DNB, FNB,<sup>b</sup> and Perumalsamy Vijayalakshmi, MS, DO<sup>a</sup>

## BACKGROUND

Optical iridectomy creates a clear entrance pupil, improving vision in patients with segmental corneal opacities. An area of clear peripheral cornea can produce retinal images compatible with good visual acuity.

## MATERIALS AND METHODS

The records of 22 children who underwent optical iridectomy from January 2002 to June 2004 were reviewed retrospectively. The optical iridectomy site was selected after slit-lamp examination. Visual acuity was assessed pre- and postoperatively by an age-appropriate method.

## RESULTS

Twenty-two children with central corneal opacities underwent the procedure. Mean age was  $10.4 \pm 12.6$  months (range, 8-24 months). Mean follow-up period was  $22.2 \pm 56.2$  months (range, 8-140 months). No intraoperative or postoperative complications were observed. Visual acuity improved to near normal in 4 children (18.2%). However, 4 children (18.2%) did not show any improvement, and 1 child lost vision. Two patients (9.1%) showed no improvement in vision despite maintaining a clear line of sight.

## CONCLUSIONS

Optical iridectomy is an alternative when penetrating keratoplasty cannot or should not be performed. (J AAPOS 2008;12:163-165)

The treatment of central corneal opacities in children has long been a subject of debate. The timing of intervention is critical to prevent the development of irreversible, dense amblyopia. Penetrating keratoplasty has an extremely high risk for failure in children,<sup>1-4</sup> with a variable visual and anatomic outcome.<sup>5-7</sup>

Optical iridectomy is a surgical alternative to penetrating keratoplasty. Miller and coworkers<sup>8</sup> suggested that an area of isolated peripheral cornea could produce retinal images compatible with 20/30 visual acuity. In this study, we performed a retrospective record review to determine the efficacy of optical iridectomy in children in whom penetrating keratoplasty was not considered.

## Materials and Methods

Case records of children who underwent optical iridectomy from January 2002 to June 2004 were reviewed. Included in the study were children who had: (1) central corneal opacity with a clear peripheral area who underwent an optical iridectomy where penetrating keratoplasty was not possible; follow-up of at least 12 months; (2) clear media (excluding the corneal opacity); and (3) normal posterior segment on ultrasound. Excluded from the

study were children with posterior segment pathologies and those who were lost to follow-up.

Children with central corneal opacities in whom penetrating keratoplasty would yield poor visual and/or anatomical outcome were chosen to undergo this procedure. All patients who presented with central corneal scars or opacities were examined for anterior segment abnormalities with a handheld slit lamp (HSO 10 handheld slit lamp, Jena, Germany). B-scan ultrasonography (OTI Scan 3D, Ontario, Canada) was performed in all patients.

Visual function was classified on the basis of fixation, with "no fixation" or "eccentric fixation" (Grade I) equivalent to  $<1/60$ , "unsteady fixation" (Grade II) equivalent to  $2/60$  to  $5/60$ , "central, not steady" (Grade III) equivalent to  $6/60$  to  $6/24$ , and "central, steady, not maintained on binocular checking" (Grade IV) equivalent to  $6/18$  or  $6/9$ . Patients with normal or near-normal vision had fixation described as "central, steady, maintained on binocular checking" (Grade V) equivalent to  $6/6$ ,<sup>9</sup> spontaneously alternating fixation (Grade VI), and "cross fixation (equal in both eyes)" (Grade V) equivalent to  $6/6$ . Children were determined to have a visual acuity of  $6/24$  or better if they were able to pick up cake sprinkles<sup>10</sup> at arm's length. We used the  $\chi^2$  test to find the association between preoperative and postoperative visual acuity.

## Surgical Technique

All procedures were performed with the patients under general anesthesia. A limbal incision was used in all cases. Viscoelastic (Viscomet, Milmet Pharma) was injected to deepen the anterior chamber and to create space between the iris and cornea. The iris was pulled outside of the limbal incision with forceps, and a maximum possible sector iridectomy was performed at the site corresponding to the maximally clear area of the overlying cornea.<sup>11</sup> Care was taken to avoid damage to the lens. The viscoelastic was then expressed, and the incision was closed with interrupted nylon sutures (Figure 1A and 1B).

Author affiliations: <sup>a</sup>Department of Paediatric Ophthalmology and Strabismus, Aravind Eye Hospitals, Tamilnadu, India; and <sup>b</sup>Pediatric Ophthalmology and Strabismus, M & J Western Institute of Ophthalmology, Civil Hospital, Ahmedabad, India

This research work is supported by grant through ORBIS International.

Submitted October 20, 2005.

Accepted October 15, 2007.

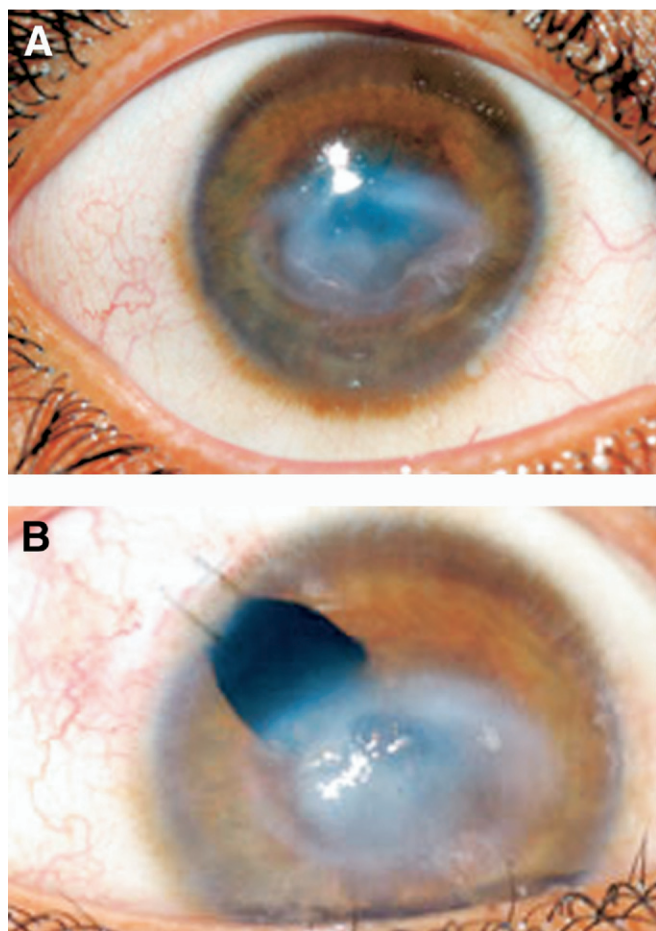
Published online January 3, 2008.

Reprint requests: Dr. P. Vijayalakshmi, Chief, Paediatric Ophthalmology & Strabismus Department, Aravind Eye Hospitals, 1, Annanagar, Madurai-625020, Tamilnadu, India (email: p.vijayalakshmi@aravind.org).

Copyright © 2008 by the American Association for Pediatric Ophthalmology and Strabismus.

1091-8531/2008/\$35.00 + 0

doi:10.1016/j.jaapos.2007.10.008



**FIG 1.** (A) Central corneal opacity prior to surgery. (B) Same eye (2 months) after optical iridectomy.

The patients were prescribed combination antibiotic–steroid eye drops (Toba DM, Milmet Pharma). They were reexamined at 1 month postoperatively and every 6 months thereafter. Examination under anesthesia was performed postoperatively to ensure that the pupil was clear and to perform retinoscopy and fundus examination. Visual acuity, anterior segment status, and refraction were assessed at every follow-up visit. Amblyopia was treated in children who had a normal unoperated eye.

## Results

Twenty-two children with central corneal opacities underwent the procedure (Table 1). The mean age was  $10.4 \pm 12.6$  months (range, 8–24 months). The mean follow-up period was  $22.2 \pm 56.2$  months (range, 12–140 months). The most common indication for optical iridectomy was congenital corneal opacities ( $n = 11$ ), including 3 (13.6%) with sclerocornea and 4 (18.2%) with Peters anomaly. Other indications included healed keratomalacia, healed keratitis, limbal dermoid, and corneal dermoid (Table 1). Table 2.

Preoperative visual acuity ranged from light perception to 6/60. Reliable vision was not recordable in 5 children (22.7%) because they were too young to cooperate. Post-

Table 1. Various causes of corneal opacities in children undergoing optical iridectomy

Indication	Number	Percentage
Congenital cornea opacities	11	50
Peter's anomaly	4	18.2
Sclerocornea	3	13.6
Others	4	18.2
Healed keratomalacia	2	9.1
Healed keratitis	3	13.6
Limbal dermoid	1	4.5
Corneal dermoid	1	4.5
Birth trauma	2	9.1
Traumatic corneal opacity	2	9.1
Total	22	100

Table 2. Distribution of visual acuity assessed on the basis of fixation of the child

Visual acuity—preoperative	Visual acuity—postoperative at last follow-up				Total
	<1/60	2/60–5/60	6/60–6/24	6/18–6/9	
<1/60	2	7	2	1	12
2/60–5/60	1	1	4	1	7
6/60–6/24	0	0	2	1	3
6/18–6/9	0	0	0	0	0
Total	3	8	8	3	22

operatively, at the last follow-up, 6 children (27.3%) had visual acuity better than or equal to 6/18. Four children (18.2%) had visual acuity better than or equal to 2/60 and 7 (31.8%) patients had visual acuity less than 2/60. There was no statistically significant improvement in visual acuity between the pre- and postoperative visits ( $P = 0.232$ ).

Three children (13.6%) did not show any improvement during the follow-up period. Visual acuity deteriorated in one child (4.5%). In 8 children (36.4%), visual acuity improved to near normal. In the remainder of the children, vision improved partially.

Five cases (22.7%) were unilateral. These patients were treated with amblyopia therapy postoperatively. The mean age in these cases was  $29.4 \pm 12.4$  months (range, 24–42 months). Of the 17 bilateral cases, only 3 (17.6%) had bilateral surgery. The remaining 14 patients (82.3%) had unilateral surgery because of asymmetry and opaque corneas. The visual acuity of 2 of the 3 bilaterally operated patients (66.6%) improved postoperatively in both the eyes (Table 3). Two patients (9.1%) showed no improvement despite maintaining a clear entrance pupil. No intraoperative or postoperative complications were encountered in any patient. At the final follow-up visit, all patients had an open, clear entrance pupil at the iridectomy site.

## Discussion

Theoretically, an optical iridectomy should allow for good vision. Miller and coworkers<sup>8</sup> placed pinholes at the edge of 8 mm dilated pupils in normal subjects and found 20/30 visual acuity and normal contrast sensitivity. They recommended that optical iridectomy be considered in

Table 3. Bilaterally operated cases

Subject no.	Age in months/sex	Indication (both eyes)	Preop vision	Right eye	Left eye
1	5 mo/M	Corneal dermoid	<1/60	6/24	6/60
2	1 mo/F	Peter's anomaly	<1/60	6/60	6/60
3	6 mo/F	Keratomalacia	<1/60	Anterior staphyloma	No ambulatory vision

appropriate cases of corneal blindness with patches of clear peripheral cornea when no donor corneal material is available.

Murali et al<sup>5</sup> stated that penetrating keratoplasty is likely to fail in children younger than 5 years of age. Poor visual outcome in their patients was associated with amblyopia, frequent graft failures, and optical distortion induced by the graft and the associated ocular pathology. Cowden<sup>6</sup> found that corneal grafts remained clear in only 13 of 66 children (19.7%) younger than 4 years of age. In that study, 3 of 8 children with Peters' anomaly (37.5%) had a clear graft on last follow-up. Only 18 children (27.3%) achieved a visual acuity of 20/100 or better.

Optical iridectomy aims to provide ambulatory vision in the patient who, if left unoperated, would end up being deeply amblyopic. In our series, only 3 of 17 patients with bilateral corneal opacities had bilateral surgery. The remaining 14 patients had unilateral surgery, mainly because their other eye had no corneal area sufficiently clear to warrant an optical iridectomy. Of the 5 patients with unilateral disease, 2 presented late; both had acquired adherent leukomas, one caused by trauma and the other caused by a healed anterior chamber granuloma. The mean age of cases with unilateral disease is high because 2 patients presented late, as both were acquired adherent leukomas, one caused by trauma and the other caused by a healed anterior chamber granuloma.

In our series, except for 2 patients who did not show any improvement, there was a variable degree of improvement in visual acuity, ranging from 6/60 to 6/12. Reliable postoperative final visual acuity could not be recorded in 5 very young patients whose vision was not assessable preoperatively.

Out of the 22 children, 13 (59.1%) were younger than 1 year of age. Previous studies have shown the long-term visual and anatomical success of penetrating keratoplasty in very young patients is highly debatable.<sup>5-7,12,13</sup> If these patients (where penetrating keratoplasty is not indicated) were left alone without any kind of intervention, they would become deeply amblyopic. Optical iridectomy avoids the problems associated with graft rejection, postoperative glaucoma, specialized care, and suture related problems.<sup>2-4</sup>

One key to the success of surgery is selection of the iridectomy site preoperatively to identify the area of max-

imum clear cornea.<sup>11</sup> The superior quadrants are the least preferred sites because they are hidden by the lids, but in many cases there may be no useful alternative.<sup>1,2</sup> In our series of patients, there were no intraoperative or postoperative complications. This procedure may prevent the development of dense amblyopia. These patients may undergo penetrating keratoplasty at a later date.

Optical iridectomy is an option in cases in whom penetrating keratoplasty is not indicated, and the procedure may prevent development of amblyopia in patients with congenital corneal opacities. In such cases, a penetrating keratoplasty can be performed at a later age, when the success rate will be greater. However, it is not yet known whether this procedure improves the likelihood of an improved visual outcome in these patients.

## Acknowledgments

The authors wish to thank Dr. Clare Gilbert for her valuable suggestions and guidance.

## References

1. Drews LC, Drews RC. Optical Iridectomy. *Am J Ophthalmol* 1964; 58:789-96.
2. Zaidman GW, Rabinowitz Y, Forstot SL. Optical iridectomy for corneal opacities in Peter's anomaly. *J Cataract Refract Surg* 1998; 24:719-22.
3. Junemann A, Gusek GC, Naumann G. Optical sector iridectomy: an alternative to perforating keratoplasty in Peters' anomaly. *Klin Monatsbl Augenheilkd* 1996;209:17-24.
4. Vajpayee RB, Sharma N, Dada T, Pushker N. Optical sector iridectomy in corneal opacities. *Cornea* 1999;18:262-4.
5. Aasuri MK, Garg P, Gokhle N, Gupta S. Penetrating keratoplasty in children. *Cornea* 2000;19:140-4.
6. Cowden JW. Penetrating keratoplasty in infants and children. *Ophthalmology* 1990;97:324-8.
7. McClellan K, Lai T, Grigg J, Billson F. Penetrating keratoplasty in children: visual and graft outcome. *Br J Ophthalmol* 2003;87:1212-4.
8. Miller D, Atebara N, Stegmann R. The role of the limbal cornea in vision. *Eye* 1989;3:128-31.
9. Zipf RF. Binocular fixation pattern. *Arch Ophthalmol* 1976;94:401-5.
10. Wright KW, Spiegel, Peter H, editors. *Pediatric ophthalmology and strabismus*, ed. 2. New York: Springer; 2003. xxiii, 1084p.
11. Singh D, Khanna KK. Improved stenopic slit for finding the optimal site for optical iridectomy. *J All India Ophthalmol Soc* 1967;15:67-8.
12. Al-Ghamdi A, Al-Rajhi A, Wagoner MD. Primary pediatric keratoplasty: Indications, graft survival, and visual outcome. *J AAPOS* 2007;11:41-7.
13. Huang PT. Penetrating keratoplasty in infants and children. *J AAPOS* 2007;11:5-6.